

Pfannenstiel scar endometriosis: a case report and literature review

*Endométriose cicatricielle sur incision de Pfannenstiel: à propos d'un cas et revue de la littérature.*Khadija BENCHAKROUNE¹, Mounir MOUKIT¹, Jaouad KOUACH^{1,2}, Driss MOUSSAOUI^{1,2}

1 Department of Obstetrics and Gynecology, Military Training Hospital Mohammed V, Rabat, Morocco.

2 Faculty of Medicine and Pharmacy, University Mohammed V, Rabat, Morocco.

Correspondance à :

Mounir MOUKIT
moukitmounir@yahoo.com

DOI:<https://doi.org/10.48087/BJMS.cr.2019.6116>

Il s'agit d'un article en libre accès distribué selon les termes de la licence Creative Commons Attribution International License (CC BY 4.0), qui autorise une utilisation, une distribution et une reproduction sans restriction sur tout support ou format, à condition que l'auteur original et la revue soient dûment crédités.

RÉSUMÉ

L'endométriose cicatricielle est une forme rare d'endométriose extrapelvienne qu'on confond généralement avec d'autres affections chirurgicales ou dermatologiques entraînant des retards dans le diagnostic. Nous rapportons le cas d'une femme de 37 ans présentant un nodule palpable adjacent à sa cicatrice césarienne. Une excision complète avec des marges claires a été réalisée et soumise à un examen histopathologique confirmant le diagnostic d'endométriose. Une sensibilisation accrue des cliniciens à cet état rare peut aider au diagnostic précoce et au traitement, avec des résultats gratifiants.

Mots-clés : césarienne ; endométriose cicatricielle ; chirurgie.

ABSTRACT

Scar endometriosis is a rare form of extrapelvic endometriosis that is usually confused with other surgical or dermatological conditions leading to delays in diagnosis. We report a case of a 37-year-old woman presenting with a palpable nodule adjacent to her cesarean scar. Complete excision with clear margins was done and sent for histopathological examination confirming the diagnosis of endometriosis. Increasing awareness of this uncommon condition among clinicians can help in early diagnosis and treatment with gratifying results.

Keywords: Caesarean section; scar endometriosis; surgery.

Introduction

Extrapelvic endometriosis is an uncommon condition in women of reproductive age defined as the presence of endometrial glands and stroma outside the pelvis [1]. Previous surgical scar on the abdominal wall is a rare site of extrapelvic endometriosis and remains a difficult condition to diagnose, because of the extreme variability in the presentation and treatment. We present a case of scar endometriosis following cesarean delivery and we review the literature to expose its epidemiologic, pathogenesis, clinical and radiological features. We discuss also the therapeutic modalities and the prevention of this rare ectopic localisation.

Case report

A 37-year-old woman presented in our department with a 3 months history of palpable nodule, adjacent to her cesarean scar. She had two previous caesarean sections and the last one being 2 years ago. Her medical history was unremarkable. She described the nodule as causing moderate cyclical pain during menses. Physical examination revealed a 2 cm deep-seated nodule, adjacent to the left lateral edge of cesarean scar. A differential diagnosis of hematoma, scar endometriosis, or abdominal abscess was made. Ultrasound showed a subcutaneous hypoechoic lesion, measuring 1.40 cm x 1.60 cm and infiltrating the adjacent tissues (Figure 1), with a single pedicle entering the mass at the periphery (Figure 1). Abdomino-pelvic Magnetic Resonance imaging (MRI) showed a subcutaneous hemorrhagic lesion at the left end of the scar, suggestive of abdominal scar endometriosis (Figure 2). There were no other lesions of pelvic endometriosis. Complete resection of the nodule with clear margins was done and the excision site was sterilized by a 0.9% sodium chloride solution. The final pathologic report revealed scar endometriosis. Evolution was uneventful and no recurrence was seen with a follow up of 3 years.

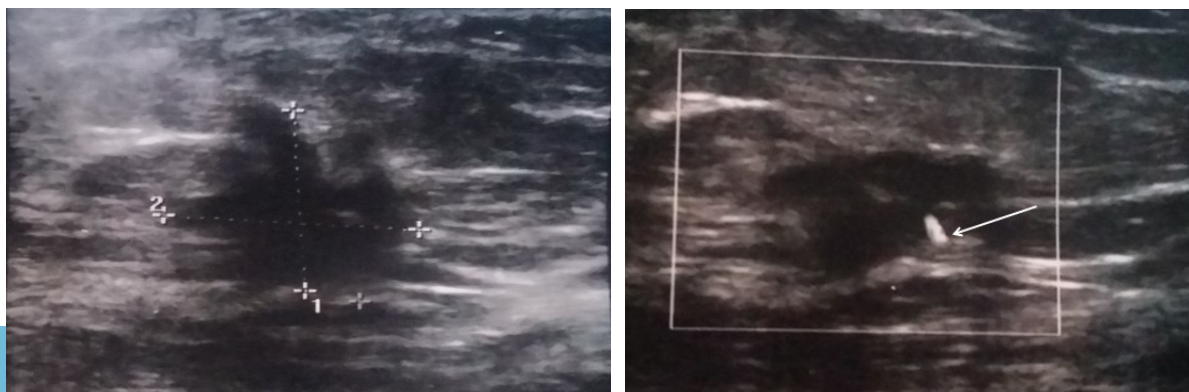


Figure 1. On the left: subcutaneous hypoechoic lesion with irregular margins infiltrating the adjacent tissues. On the right: single pedicle entering the mass at the periphery (white arrow) in color Doppler.

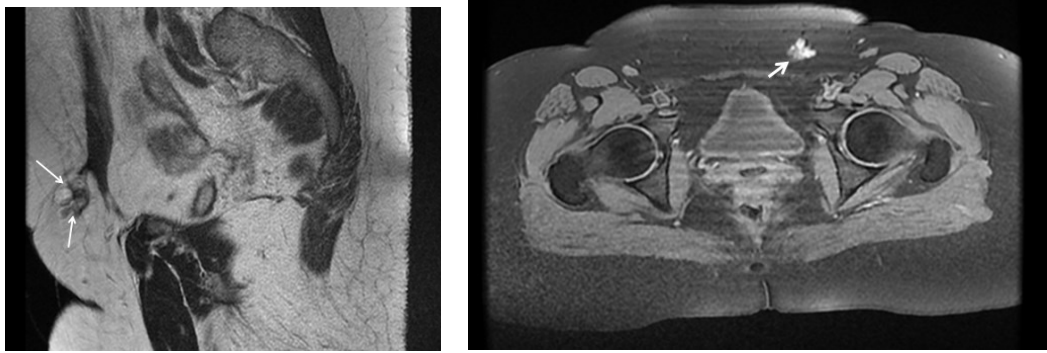


Figure 2. On the left: sagittal T2-weighted image showing a heterogeneous lesion in hypersignal primarily within the subcutaneous fat (white arrows). On the right: Axial T1-weighted image with fat suppression confirming the hemorrhagic nature and subcutaneous location of the lesion (white arrow).

Discussion

Surgical scar endometriosis is a rare entity. Its incidence after cesarean section is estimated to be in range of 0.03 to 1% [2]. In a retrospective analysis of 32 patients with abdominal incision endometriosis, 31 patients had a history of caesarean section, and only one case underwent ovarian endometrioid cystectomy [3]. Most studies report that scar endometriosis involves in operations in which uterus is opened. The pathological mechanism of this entity is most likely multifactorial and associated with iatrogenic transplantation of endometrial or placental cells within the scar tissue. When stimulated by estrogens, these cells may proliferate until they become symptomatic [4]. Association between the incisional endometriosis and concurrent occurrence of pelvic endometriosis is rare. Our patient had no history of pelvic endometriosis. Symptoms can occur several weeks to years after the initial surgery with a median of about 30 months [4]. Clinical features include palpable mass, pain, bleeding and discharge. The menstrual character of symptoms is an important diagnostic criterion, but it is present in only about 25% of cases [5]. Lesions generally vary in size from 5 to 20 mm [6]. Combined ultrasound and MRI play an important role in the diagnostic workup, although correct preoperative diagnosis is achieved in only about 20-50% of cases [7]. Francica *et al.*, in their series showed diagnostic ultrasonography features of scar endometriosis as (1) a hypoechoic inhomogeneous echo texture with internal scattered hyperechoic echoes; (2) regular margins, often speculated, infiltrating the adjacent tissue; and (3) a hyperechoic ring of variable width and continuity [8]. On color Doppler, a single avascular pedicle entering the mass at the periphery is one of the diagnostic features [8]. For lesions smaller than 1 cm, T1-weighted MRI with fat suppression appears the most sensitive in detecting these lesions. On Computed Tomography, endometrioma appears as a circumscribed solid mass, enhanced by contrast and sometimes showing hemorrhage. Preoperative diagnosis could be made by means of fine-needle aspiration cytology (FNAC) or excision biopsy. FNAC gives a rapid diagnosis and excludes malignancy. Theoretically, this procedure has the potential to seed the needle tract with cells and can cause recurrence, especially within concomitant intrapelvic endometriosis, although this has not been reported [9]. Surgical excision is the best treatment option for these superficial lesions. The frozen section is preferred during operation due to the possibility of malignancy. In fact, some cases of endometriosis can have histological changes in favor of malignancy [10]. Medical treatment can be used. The successful management of 10 cases of abdominal incision endometriosis using progesterone via local injection has been reported [11]. Prevention of abdominal scar endometriosis is based on understanding its pathogenesis. Above all, avoid unnecessary caesarean section. In addition, swabs used to wipe endometrium should not be in contact with the abdominal incision and the same applies for instruments and gloves, which have touched endometrium. Finally, suturing the uterine muscle should avoid penetrating through endometrium layers, and site incision needs to be flushed with 0.9% sodium chloride solution before closing the abdomen.

Conclusion

Scar endometriosis should be suspected in any woman of reproductive age with pain and mass at scar site after obstetric surgery. Work-up must include both imaging and histopathological findings. Surgical treatment is recommended to excise the lesion completely.

Acknowledgments: We are thankful to the patient who permitted us to present his history in this report.

Conflicts of interest: None declared.

Références

- Patterson GK, Winburn GB. Abdominal wall endometriomas: report of eight cases. *Am Surg* 1999; 65:36-39.
- Gaunt A, Heard G, McKain ES, Stephenson BM. Caesarean scar endometrioma. *Lancet* 2004; 364:368.
- Zhu Z, Al-Beiti MAM, Tang L, et al. Clinical characteristic analysis of 32 patients with abdominal incision endometriosis. *J Obstet and Gynecol* 2008; 28:742-745.
- Teng CC, Yang HM, Chen KF, et al. Abdominal wall endometriosis: an overlooked but possibly preventable complication. *Taiwan J Obstet Gynecol* 2008; 47:42-48.
- Hensen JH, Van Breda Vriesman AC, Puylaert JB. Abdominal wall endometriosis: clinical presentation and imaging features with emphasis on sonography. *AJR* 2006;616-620.
- Blanco RG, Parthivel VS, Shah AK, et al. Abdominal wall endometriomas. *Am J Surg* 2003; 185:596-598.
- Hassanin-Negila A, Cardini S, Ladam-Marcus V, et al. Endometriomas of the abdominal wall: imaging findings. *J Radiol* 2006; 87:1691-1695.
- Francica G, Giardiello C, Angelone G, et al. Abdominal wall endometriomas near cesarean delivery scars: sonographic and color Doppler findings in a series of 12 patients. *J Ultrasound Med* 2003; 22:1041e7.
- Gupta RK. Fine-needle aspiration cytodiagnosis of endometriosis in cesarean section scar and rectus sheath mass lesions: a study of seven cases. *Diagn Cytopathol* 2008; 36:224-226.
- Leng J, Lang J, Guo L, et al. Carcinosarcoma arising from atypical endometriosis in a cesarean section scar. *International Journal of Gynecological Cancer* 2006; 16:432-435.
- Chunlei S, Xiudong R. Abdominal incision endometriosis: treat by progesterone via local injection. *Banausic Medical Journal* 2004; 20:1180.